

**THE S.T.A.B.L.E. Program**

**Gestational Age Assessment of the Newborn**

**Kristine A. Karlsen MSN, RNC, NNP**  
 Author  
 National Program Director, Founder  
 The S.T.A.B.L.E. Program  
 Park City, Utah  
 stable@stableprogram.org


**PowerPoint® Design**  
**Mary Puchalski MS, RNC, APN/CNS**  
 Lombard, Illinois  
 mary@stableprogram.org

**Medical Illustrations**  
**John Gibb MA**

© K. Karlsen 2006

**Principles of Exam**

- Timing
  - ◆ Most reliable if performed by 12 hours of life
- Keep infant warm



© K. Karlsen 2006

**Ballard Gestational Age Assessment**

	-1	0	1	2	3	4	5
<b>Skin</b>	Sticky Friable Transparent	Gelatinous Red Translucent	Smooth pink Visible veins	Superficial peeling and/or rash Few veins	Cracking Pale areas Few veins	Parchment Deep cracking No vessels	Leathery Cracked Wrinkled
<b>Lanugo</b>	No lanugo	Sparse lanugo	Abundant lanugo	Thinny Lanugo	Bald Areas	Mostly bald	
<b>Plantar surface</b>	Heel- toe 40-50 mm <40 = -2	Heel- toe 50 mm No crease	Faint red marks	Anterior creases, posterior crease only	Creases anterior 2/3	Creases over entire sole	
<b>Breast</b>	Hypercapitula	Barely perceptible	Flat areola no bud	Slightly curved pinna Soft slow recoil	Raised areola 1-2 mm bud	Full areola 5-10 mm bud	
<b>Eyes / ears</b>	Lids fused Loosely: -1 Tightly: -2	Lids open Pinna flat Stays folded	Slightly curved pinna Soft slow recoil	Well-curved pinna Soft but ready recoil	Formed and firm Instant recoil	Thick cartilage Ear stiff	
<b>Male Genitals</b>	Scrotum flat, smooth	Scrotum empty Fair rugae	Testes in upper canal Rare rugae	Testes descending Fair rugae	Testes down Good rugae	Testes pendulous Deep rugae	
<b>Female Genitals</b>	Clitoris prominent Labia flat	Prominent clitoris Small labia 50/50	Prominent clitoris Enlarging minora	Majora and minora equally prominent	Majora large Minora small	Majora cover clitoris and minora	
<b>Neuromuscular Maturity</b>							
<b>Posture</b>							
<b>Square window (vertical)</b>							
<b>Arm recoil</b>							
<b>Popliteal angle</b>							
<b>Scarf sign</b>							
<b>Heel to ear</b>							

Adapted from: Ballard et al. (1991) *J Pediatr.*, 119(3): 417-423.

© K. Karlsen 2006

**Ballard Exam • Physical Maturity**

	-1	0	1	2	3	4	5
<b>Skin</b>	Sticky Friable Transparent	Gelatinous Red Translucent	Smooth pink Visible veins	Superficial peeling and/or rash Few veins	Cracking Pale areas Rare veins	Parchment Deep cracking No vessels	Leathery Cracked Wrinkled
<b>Lanugo</b>	No lanugo	Sparse lanugo	Abundant lanugo	Thinning Lanugo	Bald areas	Mostly bald	
<b>Plantar surface</b>	Heel- toe 40-50 mm <40 = -2	Heel- toe > 50 mm No crease	Faint red marks	Anterior transverse crease only	Creases anterior 2/3	Creases over entire sole	
<b>Breast</b>	Im-perceptible	Barely perceptible	Flat areola no bud	Stippled areola 1-2 mm bud	Raised areola 3-4 mm bud	Full areola 5-10 mm bud	
<b>Eyes / ears</b>	Lids fused: Loosely: -1 Tightly: -2	Lids open Pinna flat Stays folded	Slightly curved pinna Soft slow recoil	Well-curved pinna Soft but ready recoil	Formed and firm Instant recoil	Thick cartilage Ear stiff	
<b>Male Genitals</b>	Scrotum flat, smooth	Scrotum empty Fair rugae	Testes in upper canal Rare rugae	Testes descending Fair rugae	Testes down Good rugae	Testes pendulous Deep rugae	
<b>Female Genitals</b>	Clitoris prominent Labia flat	Prominent clitoris Small labia minora	Prominent clitoris Enlarging minora	Majora and minora equally prominent	Majora large Minora small	Majora cover clitoris and minora	

© K. Karlsen 2006

**Ballard Gestational Age Assessment**

A detailed monograph and explanation about how to perform the Ballard exam (written by Dr. Ballard), may be found at [www.BallardScore.com](http://www.BallardScore.com)

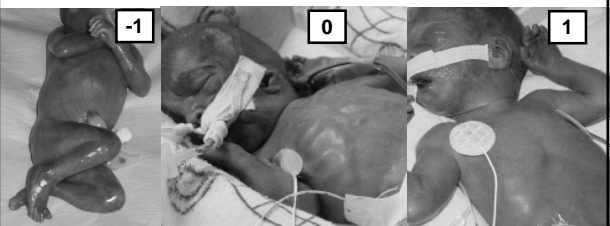
Adapted from: Ballard et al. (1991) *J Pediatr.*, 119(3): 417-423.

Neuromuscular illustrations were adapted with permission of Dr. Ballard

© K. Karlsen 2006

**Skin**



	-1	0	1	2	3	4	5
<b>Skin</b>	Sticky Friable Transparent	Gelatinous Red Translucent	Smooth pink Visible veins	Superficial peeling and/or rash Few veins	Cracking Pale areas Rare veins	Parchment Deep cracking No vessels	Leathery Cracked Wrinkled



© K. Karlsen 2006

### Skin

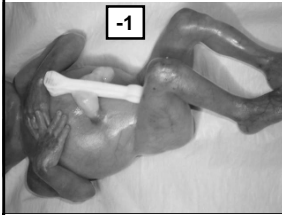
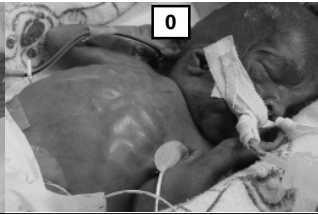
-1	0	1	2	3	4	5
Sticky Friable Transparent	Gelatinous Red Translucent	Smooth pink Visible veins	Superficial peeling and/or rash Few veins	Cracking Pale areas Rare veins	Parchment Deep cracking No vessels	Leathery Cracked Wrinkled

\*S.T.A.B.L.E.  
© K. Karlsen 2006

### Lanugo




-1	0	1	2	3	4
No lanugo	Sparse	Abundant	Thinning	Bald areas	Mostly bald

\*S.T.A.B.L.E.  
© K. Karlsen 2006

### Skin

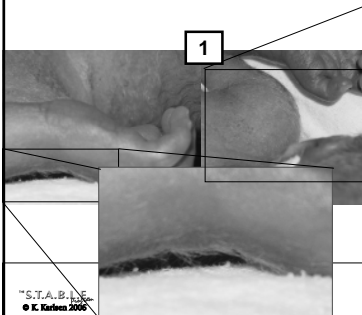

-1	0	1	2	3	4	5
Sticky Friable Transparent	Gelatinous Red Translucent	Smooth pink Visible veins	Superficial peeling and/or rash Few veins	Cracking Pale areas Rare veins	Parchment Deep cracking No vessels	Leathery Cracked Wrinkled

\*S.T.A.B.L.E.  
© K. Karlsen 2006

### Lanugo

-1	0	1	2	3	4
No lanugo	Sparse	Abundant	Thinning	Bald areas	Mostly bald

\*S.T.A.B.L.E.  
© K. Karlsen 2006

### Lanugo

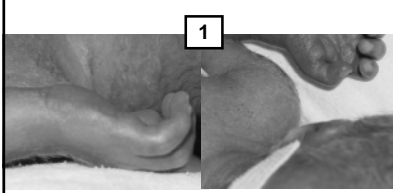

-1	0	1	2	3	4
No lanugo	Sparse	Abundant	Thinning	Bald areas	Mostly bald

- Begins to appear 24 – 25 weeks
- Abundant across shoulders and upper back by 28 weeks
- With increasing gestation
  - ◆ Lower back area thins first
  - ◆ Bald areas appear over lumbo-sacral area
  - ◆ Mostly bald by term
- Amount and location may vary with nutritional status, ethnicity, hormonal and metabolic factors

\*S.T.A.B.L.E.  
© K. Karlsen 2006

### Lanugo


-1	0	1	2	3	4
No lanugo	Sparse	Abundant	Thinning	Bald areas	Mostly bald

\*S.T.A.B.L.E.  
© K. Karlsen 2006

### Lanugo

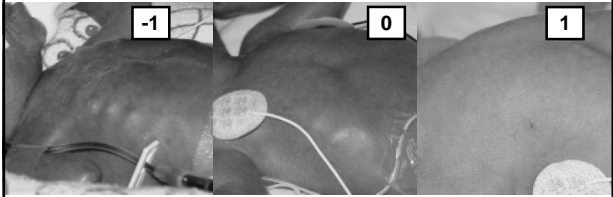
-1	0	1	2	3	4
No lanugo	Sparse	Abundant	Thinning	Bald areas	Mostly bald



\*S.T.A.B.L.E.  
© K. Karlsen 2006

### Breast


-1	0	1	2	3	4
Im-perceptible	Barely perceptible	Flat areola no bud	Stippled areola 1-2 mm bud	Raised areola 3-4 mm bud	Full areola 5-10 mm bud



\*S.T.A.B.L.E.  
© K. Karlsen 2006

### Plantar Surface

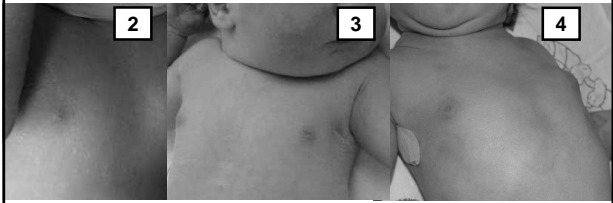
-1	0	1	2	3	4
Heel-toe 40 - 50 mm < 40 = -2	> 50 mm No crease	Faint red marks	Anterior transverse crease only	Creases anterior 2/3	Creases over entire sole



\*S.T.A.B.L.E.  
© K. Karlsen 2006

### Breast


-1	0	1	2	3	4
Im-perceptible	Barely perceptible	Flat areola no bud	Stippled areola 1-2 mm bud	Raised areola 3-4 mm bud	Full areola 5-10 mm bud



\*S.T.A.B.L.E.  
© K. Karlsen 2006

### Plantar Surface


-1	0	1	2	3	4
Heel-toe 40 - 50 mm < 40 = -2	> 50 mm No crease	Faint red marks	Anterior transverse crease only	Creases anterior 2/3	Creases over entire sole



\*S.T.A.B.L.E.  
© K. Karlsen 2006

### Eye and Ear

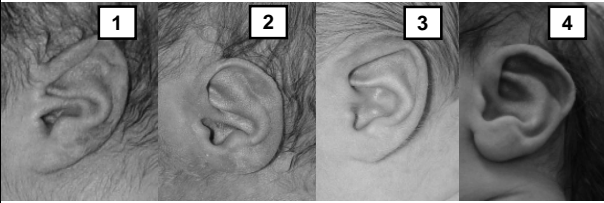
-1	0	1	2	3	4
Lids fused: Loosely: -1 Tightly: -2	Lids open Pinna flat Stays folded	Slightly curved pinna Soft slow recoil	Well-curved pinna Soft but ready recoil	Formed and firm Instant recoil	Thick cartilage Ear stiff



\*S.T.A.B.L.E.  
© K. Karlsen 2006

### Eye and Ear

-1	0	1	2	3	4
Lids fused: Loosely: -1 Tightly: -2	Lids open Pinna flat Stays folded	Slightly curved pinna Soft slow recoil	Well-curved pinna Soft but ready recoil	Formed and firm Instant recoil	Thick cartilage Ear stiff



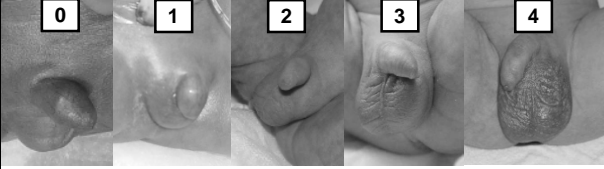
S.T.A.B.L.E.  
© K. Karlsen 2006

### Ballard Exam • Neuromuscular Maturity

	-1	0	1	2	3	4	5
Posture							
Square window (wrist)							
Arm recoil							
Popliteal angle							
Scarf sign							
Heel to ear							

### Genitalia • Male

-1	0	1	2	3	4
Scrotum flat, smooth	Scrotum empty Faint rugae	Testes in upper canal Rare rugae	Testes descending Few rugae	Testes down Good rugae	Testes pendulous Deep rugae




S.T.A.B.L.E.  
© K. Karlsen 2006

### Principles of Neuromuscular Exam

- Positioning
  - Head midline
  - Hips flat
- Reliability of exam altered by:
  - Sedation
  - Anesthesia
  - Paralysis
  - Critically ill state
  - Breech position

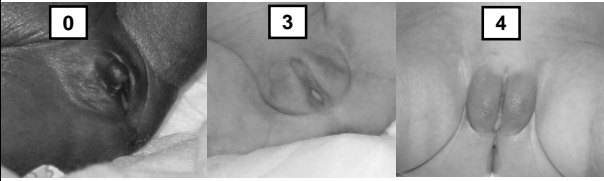
**⚠️ Neuromuscular assessment may be too stressful for premature and sick infants → should be performed by skilled neonatal ICU personnel once infant stabilized and able to tolerate the exam**



S.T.A.B.L.E.  
© K. Karlsen 2006

### Genitalia • Female


-1	0	1	2	3	4
Clitoris prominent Labia flat	Prominent clitoris Small labia minora	Prominent clitoris Enlarging minora	Majora and minora equally prominent	Majora large Minora small	Majora cover clitoris and minora



S.T.A.B.L.E.  
© K. Karlsen 2006

### Posture

-1	0	1	2	3	4



S.T.A.B.L.E.  
© K. Karlsen 2006

### Posture

-1	0	1	2	3	4

™S.T.A.B.L.E.  
© K. Karlsen 2006

### Square Window

-1	0	1	2	3	4

™S.T.A.B.L.E.  
© K. Karlsen 2006

### Square Window

-1	0	1	2	3	4

- Assesses wrist flexibility and/or resistance to extensor stretching at the wrist
- Press gently on knuckles to straighten fingers
- Apply gentle pressure on back of hand close to fingers → avoid wrist rotation
- Stop pressing when resistance felt
- Angle decreases as gestational age increases

™S.T.A.B.L.E.  
© K. Karlsen 2006

### Arm Recoil

-1	0	1	2	3	4

- Tests for passive flexor tone of biceps muscle
- Test one arm at a time in order to avoid the Moro reflex
- Supine position
- Hold infant's hand
- Briefly flex arm → then momentarily extend arm and release hand
- Scores based on angle of recoil when arms return to flexion

™S.T.A.B.L.E.  
© K. Karlsen 2006

### Square Window

-1	0	1	2	3	4

™S.T.A.B.L.E.  
© K. Karlsen 2006

### Arm Recoil

-1	0	1	2	3	4

™S.T.A.B.L.E.  
© K. Karlsen 2006

### Popliteal Angle

-1	0	1	2	3	4	5
180°	160°	140°	120°	100°	90°	<90°

- Assesses maturation of passive flexor tone about the knee joint
- Refrain from touching hamstrings (the muscle group being tested) during maneuver
- Thigh placed in knee-chest position with knee fully flexed
- Allow infant to relax, then grasp foot at sides
- Extend leg until resistance is felt
- Estimate angle behind the knee
- Measurement unreliable if frank breech in utero

™S.T.A.B.L.E.  
© K. Karlsen 2006

### Scarf Sign

-1	0	1	2	3	4
neck	axillary line	nipple line	xyphoid process	nipple line	axillary line

- Tests passive tone of the posterior shoulder girdle flexor muscles
- Supine position with head midline
- Hold infant's hand across chest and use thumb of other hand to gently push elbow across chest
- Or, gently pull arm across chest (shown in photos)
- Stop when resistance is felt
- Scores based on position of elbow at landmarks

™S.T.A.B.L.E.  
© K. Karlsen 2006

### Popliteal Angle

-1	0	1	2	3	4	5
180°	160°	140°	120°	100°	90°	<90°

**0**

**1**

™S.T.A.B.L.E.  
© K. Karlsen 2006

### Scarf Sign

-1	0	1	2	3	4
neck	axillary line	nipple line	xyphoid process	nipple line	axillary line

**1**

**2**

™S.T.A.B.L.E.  
© K. Karlsen 2006

### Popliteal Angle

-1	0	1	2	3	4	5
180°	160°	140°	120°	100°	90°	<90°

**2**

**3**

**4**

™S.T.A.B.L.E.  
© K. Karlsen 2006

### Scarf Sign

-1	0	1	2	3	4
neck	axillary line	nipple line	xyphoid process	nipple line	axillary line

**3**

**4**

™S.T.A.B.L.E.  
© K. Karlsen 2006

### Heel-to-Ear

-1	0	1	2	3	4
ear	nose	chin	nipple line	umbilical area	femoral crease

- Tests for passive flexion or resistance to extension of posterior hip flexor muscles
- Refrain from touching gluteus muscle (the muscle group being tested) during maneuver
- Rest leg alongside the body
- Grasp foot along both sides
- Gently pull toward ear until resistance felt
- Scores based on location of heel to landmarks
- Measurement unreliable if frank breech in utero

\*S.T.A.B.L.E.  
© K. Karlsen 2006

### Gestational Age Evaluation

■ Sum scores

	Physical Maturity										
	-1	0	1	2	3	4	5				
Skin	Sticky Fruity Translucent	Glistening Red Translucent	Smooth pink Visible veins	Superficial erythema rash	Cracking Pale areas Bare veins	Purpleness Deep cracking No mottling	Leathery Cracked Wrinkled				
Lanugo	No lanugo	Scarcely lanugo	Abundant lanugo	Thinning lanugo	Bald areas	Mostly bald					
Plantar sulci/ridges	Head line 20-55 mm < 48 x 2	No crease	Faint red marks	Thymus translucent	Creases entirely 2/3	Creases entirely					
Breast	Not perceptible	Barely perceptible	Fine nipple on bud	Enlarged areola 2-3 mm bud	Raised areola 2-4 mm bud	Full areola 5-10 mm bud					
Eyes / ears	Like head: Loose -1 Tight: -2	Lids open Pinna flat Slits folded	Slightly curved pinna No ear canal	Thymus pinna Ear bud empty	Furrowed and sutured	Thymus pinna Open ridge					
Male Genitals	Scrotum flat, smooth	Scrotum empty Faint ridge	Thymus open "canal" Bare ridge	Thymus descending Ear ridge	Thymus down Good ridge	Thymus penile Open ridge					
Female Genitals	Clitoris prominent Labia fat	Prominent clitoris Small labia entire	Prominent clitoris Enlarging entire	Major mora slightly prominent	Major large Minor small	Major cover clitoris and entire					
Neuromuscular Maturity											
Posture											
Square window (heel)											
Arm recoil											
Popliteal angle											
Scarf sign											
Heel to ear											

10 + 15 = 25

\*S.T.A.B.L.E.  
© K. Karlsen 2006

### Heel-to-Ear

-1	0	1	2	3	4
ear	nose	chin	nipple line	umbilical area	femoral crease

\*S.T.A.B.L.E.  
© K. Karlsen 2006

### Gestational Age Evaluation

■ Sum scores

- ◆ Neuromuscular
- ◆ Physical maturity

■ Total score correlates to weeks gestation

Score	Wks
-10	20
-5	22
0	24
5	26
10	28
15	30
20	32
25	34
30	36
35	38
40	40
45	42
50	44

10 + 15 = 25

\*S.T.A.B.L.E.  
© K. Karlsen 2006

### Heel-to-Ear

-1	0	1	2	3	4
ear	nose	chin	nipple line	umbilical area	femoral crease

\*S.T.A.B.L.E.  
© K. Karlsen 2006

A detailed monograph and explanation about how to perform the Ballard exam (written by Dr. Ballard), may be found at [www.BallardScore.com](http://www.BallardScore.com)